



Original Article

Comparison between Nanochitosane and Calcium Hydroxide on BMP-2 and TGF- β 1 Levels in Pulp Capping Treatment (In Vivo Study)

Noor Hafida Widyastuti^{1,*} , Risya Cilmiaty² , Adi Prayitno² , Brian Wasita³ , Soetrisno Soetrisno⁴

¹Department of Conservative Dentistry, Faculty of Dentistry, Universitas Muhammadiyah Surakarta, Indonesia

²Department of Oral Disease, Faculty of Medicine, Sebelas Maret University, Central Java, Surakarta, Indonesia

³Department of Anatomical Pathology, Sebelas Maret University, Central Java, Surakarta, Indonesia

⁴Department of Obstetrics and Gynaecology, Faculty of Medicine, Sebelas Maret University, Central Java, Surakarta, Indonesia

ARTICLE INFO

Article history

Receive: 2024-11-19

Received in revised: 2024-01-26

Accepted: 2024-01-28

Manuscript ID: JMCS-2401-2442

Checked for Plagiarism: **Yes**

Language Editor:

Dr. Fatima Ramezani

Editor who approved publication:

Dr. Majid Darroudi

DOI:10.26655/JMCHMSCI.2024.5.4

KEYWORDS

Reversible pulpitis

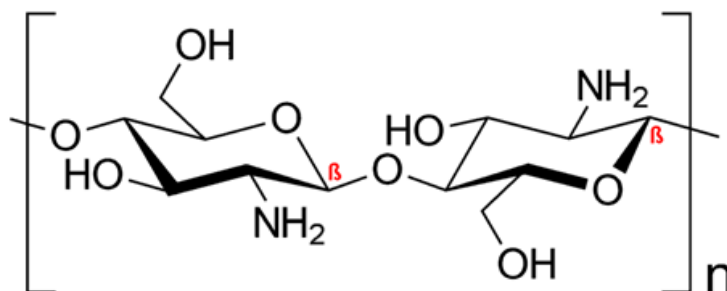
Nanochitosan

Pulp capping

ABSTRACT

Pulp capping treatment cures reversible pulpitis to restore regular pulses without feeling pain. Calcium hydroxide is often used for pulp capping treatment. Nanochitosan is chitosan in nanoparticle. Chitosan has antibacterial and anti-inflammatory properties and fulfills the requirements to be used as a pulp capping material and applied to the wound area. The study was done *in vivo* in a laboratory using a sample of the Sprague-Dawley mole Sprague Dawley. The study uses four groups: healthy rat groups, reversible pulpitis, given the $\text{Ca}(\text{OH})_2$, and the reversible pulpitis group, in which we are given nanochitosan. After 28 days, the BMP-2 and TGF- β 1 levels were measured using ELISA. The results of One-way ANOVA test showed a significant value of <0.001 for BMP-2 level and $p=0,016$ for TGF- β 1 level. There is a significant difference in the mean level of BMP-2 and TGF- β 1 in the four groups. This study showed that pulpitis reversible rats that received pulp medicament with nanochitosan had higher levels of BMP-2 and TGF- β 1 than those given calcium hydroxide.

GRAPHICAL ABSTRACT



* Corresponding author: Noor Hafida Widyastuti

✉ E-mail: nhw184@ums.ac.id

© 2024 by SPC (Sami Publishing Company)

Introduction

Direct pulp capping is a treatment that is performed when the pulp is exposed to iatrogenic factors, resulting in perforation of the pulp tissue [1]. Pulp cap treatment is performed by placing medicament material as a barrier over the pulp tissue. Inflammation can be slowed down, the pulp tissue can be protected from outside influences, and reparative dentin can form more easily. This is the main goal of pulp treatment [2]. The formation of reparative dentin begins with the formation of a fibronectin matrix, which is tubular and irregular. It is made up of a lot of fibronectin and acts as a storage area for growth factors like TGF- β and molecules that help odontoblast-like cells differentiate [3]. Eugenol is one of the pulp-capping medicaments [4]. The medicament material often used in treating pulp capping is calcium hydroxide Ca(OH)₂. However, calcium hydroxide has drawbacks, including poor adhesion to dentin, high solubility, and mechanical instability that results in tunnel defects [5]. The high power of hydrogen (pH) in calcium hydroxide can cause liquidation necrosis in the superficial layer of the pulp [6]. Necrosis of the pulp tissue can increase the expression of nuclear factor kappa B (NF- κ B) and proinflammatory cytokines; this will increase vascular permeability and the movement of neutrophil cells to the area of injury if the pulp tissue is in direct contact with these materials so that persistent inflammation can occur [7].

A technological innovation in dentistry, an effort to overcome the lack of calcium hydroxide, is utilizing natural biomaterials based on polysaccharides sourced from animals, one of which is chitosan [8]. Chitosan is a polysaccharide produced from chitin [9]. Chitin is a polymeric compound in most shelled marine animals, such as shrimp, crabs, lobsters, fish scales, clams, and crabs. Isolation of chitosan with various raw materials used is more or less the same in its production, namely through the stages of demineralization, deproteination, and deacetylation. However, the difference is the degree of deacetylation in each of these materials

[10].

Chitosan has bioactive, anti-inflammatory, and non-toxic properties and plays an active role in wound healing, bone repair, and haemostasis. Therefore, the use of chitosan is now being developed as an alternative medicament in dentistry [11]. Chitosan monomer promotes tissue regeneration in dental pulp wounds. The results show that chitosan accelerates cell proliferation, and the regeneration process of the exposed pulp can ideally occur when the inflammatory process is minimal. According to another study, using pulp capping material mixed with chitosan hydrogel would speed up the healing of vital pulp by encouraging the production of healing dentin. One way that chitosan can help reduce inflammation is by blocking MAPK p38. This protein is very important for cell differentiation and making cytokines that cause inflammation [12].

Transforming Growth Factor β 1 TGF- β 1 is a growth factor included in the group of growth factors that play a role in proliferation, migration, and differentiation in pulp cells [13]. This study using fish scale nanochitosan has never been carried out before. This study compares nanochitosane and calcium hydroxide on BMP-2 and TGF- β 1 levels in direct pulp capping in teeth with reversible pulpitis *in vivo* studies.

Materials and Methods

This type of study is done in an experimental laboratory. Extracts were made at the UMS Pharmacy Laboratory, and animal treatments were carried out at the UNISULA Laboratory. The Health Research Ethics Commission, Faculty of Medicine, Universitas Muhammadiyah Surakarta, No. 3642/A.1/KEPK-FKUMS/VIII/2021, has granted ethical approval for this research.

The initial step in the treatment of the teeth of experimental animals is to perform asepsis in the control group and the case group using a cotton pellet that has been applied with povidone-iodine and clamped by tweezers, followed by a circular motion from the inside to the outside in the area

to be treated, and then intramuscular anesthesia was done with 0.2 cc of ketamine. Retraction of the rat's upper jaw using a check retractor or tweezers to make it easier to see the work area. The preparation of the maxillary first molars using a fissure diamond bur with a high-speed handpiece, starting at the occlusal position of the tooth, was drilled in a direction perpendicular to the axis of the tooth to a depth of 1 mm with a diameter of 2 mm to a thin layer above the roof of the pulp. A perforation was made using a probe. Afterwards, the depth of the burial was checked using a 10 K file. The bleeding area of the cavity was cleaned using a cotton pellet and irrigated with saline solution, and then dried with sterile dry cotton. Furthermore, the rats were given treatment according to each group. Group I (healthy mice), Group II (reversible pulpitis rats), Group III (reversible pulpitis+Ca(OH)₂), and Group IV (reversible pulpitis+Chitosan red snapper scales).

Thereafter, the dry cavity was closed directly using Cavit (3M ESPE, UK, and Ireland). The mice were then placed in the cage according to each treatment group. The rats were allowed to stand for 72 hours to see a decrease in their pain response. The data were tested using IBM SPSS 23 software and analysed with the One-way ANOVA test and post-hoc with the least significant difference (LSD) test.

Results and Discussion

The subject of this study was a group of Sprague Dawley rats that had been given pulp capping medicament. The results of the study level for BMP-2 are presented in Table 1.

Based on Table 1, it is known that there is a difference in the mean level of BMP-2 in the four groups. The group IV (reversible pulpitis rats treated with nanochitosan had the highest level of BMP-2. The results of the One-way ANOVA test showed a significant value of 0.000 ($p < 0.05$), meaning that there was a significant difference between the four groups in this study. The post-hoc test is Least Significant Difference which is used to see a significant difference between groups is presented in Table 2.

The interpretation of the results of LSD test is that there is a significant difference in BMP-2 level ($p < 0.05$) in group I to group II, group I to group III, group I to group IV, group II to group IV, and group III to group IV. Other groups such as group II against group III showed that was not significant between group II to group III. The results of the study level of TGF- β 1 are summarized in Table 3. Based on Table 3, it is known that there is a difference in the mean level of TGF- β 1 in the four groups. The group IV (reversible pulpitis rats treated with nanochitosan had the highest level of TGF- β 1.

The results of the One-way ANOVA test showed a significant value of 0.0016 ($p < 0.05$), meaning that there was a significant difference between the four groups in this study.

Table 1: The results of mean, standard deviation, and One-way ANOVA test for BMP2 level

Group	BMP-2 ($\bar{x} \pm SD$)	Shapiro wilk	Levene test	One-way ANOVA Sig.
I (Healthy Rat)	418.54±16.24	0.364	0.764	0.000
II (Reversible Pulpitis)	399.98±11.25	0.920		
III (reversible pulpitis+Ca(OH) ₂)	394.93±10.49	0.274		
IV (reversible pulpitis+nanochitosan)	477.50±17.21	0.786		

Table 2: Results of LSD post-hoc test for BMP-2 levels in each treatment group

Group	I	II	III	IV
I	-	0.034*	0.009*	0.000*
II	0.034*	-	0.542	0.000*
III	0.009*	0.542	-	0.000*
IV	0.000*	0.000*	0.000*	-

Table 3: The results of mean, standard deviation, and One-way ANOVA test for TGF- β 1

Group	BMP-2 (x + SD)	Shapiro wilk	Levene test	One-way ANOVA Sig.
I (Healthy Rat)	439.38± 35.74	0.839	0.217	0.016
II (Reversible Pulpitis)	417.05±29.27	0.868		
III (reversible pulpitis+Ca(OH) ₂)	488,31 ±41,71	0.05		
IV (reversible pulpitis+nanochitosan)	501,37± 70,10	0.714		

The post-hoc test is Least Significant Difference which is used to see a significant difference between groups is indicated in [Table 4](#).

The interpretation of the results of the LSD test is that there is a significant difference in TGF- β 1. Level ($p < 0.05$) in Group I to Group IV, Group II to Group III, and Group II to Group IV. Other groups, such as Group I to Group II, Group I to Group III, and II to Group III, showed that there was no significant.

The pulp roof opened when a round diamond burst into the injured mice's teeth. Microorganisms will enter the pulp through the exposed pulp, irritating, and worsening [14]. The initial odontoblast cells will respond defensively to the inflammation by regaining their capacity to facilitate healing. Reactionary dentin is formed when initial odontoblast cells are not injured by modest pulp tissue injury. More severe damage, however, will cause the original odontoblast cell to die and be replaced with a cell that resembles an odontoblast [15]. Calcium hydroxide causes the pulp tissue to develop necrosis. This condition is related to the firm-base properties of calcium hydroxide. High pH in calcium hydroxide helps release protein and growth factor (TGF- β 1). On the other hand, the strong base properties will cause necrosis layers to form when in contact with the pulp tissue and can induce local inflammation [16]. The hydroxyl (OH⁻) ions in calcium hydroxide are highly reactive free radicals that can cause cell membrane damage, DNA damage, and protein decomposition, resulting in cell death [17]. The content of N-acetyl D-glucosamine in chitosan will form a cross-bond with glycosaminoglycans and glycoproteins that activate the protein growth factors BMP-2 and TGF- β 1 [18]. High levels of deacetylation make chitosan more biocompatible while wounds are healing, especially when cells

that look like odontoblasts begin to form [19]. N-acetyl D-glucosamine will bind crosswise to glycosaminoglycans and glycoproteins involved in TGF- β 1 activation. Chitosan can enhance the TGF- β 1 function, which is responsible for inducing the production of cells resembling odontoblasts, by shielding them from heat and enzyme degradation [20]. The tight sealing affects the creation of restoration in pulp through the differentiation of pulp cells to form reparative dentin. Chitosan has a better sealing ability than calcium hydroxide because of its highly effective cationic polyelectrolyte properties when interacting with surface and negatively charged biomolecules. Chitosan has an amino group that can bind hydroxyl particles to dentin. The ability of the inner chitosan to be a good seal can reduce bacterial contamination entering the pulp so that the inflammation does not continue and becomes bigger [21]. Chitosan can accelerate wound healing through fibrinogen mediators activated by growth factors. Because chitosan can combine with heparin polyanions to form polyelectrolyte complexes, it can make growth factors BMP-2 and TGF- β 1 do their job of stimulating cell differentiation better and for longer [22]. For a variety of reasons, fungal mycelia and higher edible fungi are seen as an alluring substitute for the synthesis of chitin and chitosan biopolymers. They possess a multitude of distinct biological and physicochemical traits. Commercial products that are now on the market rely on marine sources instead than fungal cell walls, despite their many advantages. [23]. Chitosan is a good adsorbent for the removal of organic colours because it is nontoxic, eco-friendly, and contains a lot of amine and hydroxyl groups. It was discovered that New modified chitosan Schiff base (EP-CS-SB) was a good option for cationic dye removal [24].

Table 4: Results of LSD post-hoc test for TGF- β 1 levels in each treatment group

Group	I	II	III	IV
I	-	0.419	0.086	0.033*
II	0.419	-	0.016*	0.005*
III	0.086	0.016*	-	0.635
IV	0.033*	0.005*	0.635	-

To achieve greater removal efficiency in a cost-effective manner, it is recommended to conduct testing under ideal conditions to determine how dyes degrade [25]. Fish medicine can benefit from the antibacterial and immunomodulatory properties of marine bio-sourced chitosan nanoparticles (CSNP) [26].

Conclusion

Pulpitis-reversible rats that added pulp medicament with nanochitosane had higher levels of BMP-2 and TGF- β 1 than those given calcium hydroxide.

Acknowledgments

The authors appreciate and are thankful for the support from Universitas Muhammadiyah Surakarta and Sebelas Maret University.

Conflict of Interest

The authors reported no potential conflict of interest in this study.

Author's Contribution

All authors contributed to data analysis, drafting, and revising the article and agreed to be responsible for all aspects of this work.

ORCID

Noor Hafida Widyastuti

<https://orcid.org/0000-0001-7210-1319>

Risya Cilmiaty

<https://orcid.org/0000-0001-9351-5246>

Adi Prayitno

<https://orcid.org/0000-0001-5548-4848>

Brian Wasita

<https://orcid.org/0000-0002-5501-3541>

Soetrisno Soetrisno

<https://orcid.org/0000-0003-0404-3676>

References

- [1]. Kunert M., Lukomska-Szymanska M., Bio-inductive materials in direct and indirect pulp capping—a review article, *Materials*, 2020, **13**:1204 [Crossref], [Google Scholar], [Publisher]
- [2]. Sonia E.L., Cahyani C. The Effect of Odontoblast Formation on Reversible Pulpitis After Application of Calcium Hydroxide and Mineral Trioxide Aggregate: Literature Review. *Atlantis Press International BV*, 2023 [Crossref], [Publisher]
- [3]. Widyastuti N.H., Nurwita A.R., A Review on Dental Material about Biocompatibility Properties, *Journal of Medicinal and Chemical Sciences*, 2022, **5**:695 [Crossref], [Google Scholar], [Publisher]
- [4]. Sari N.D.A.M., Hafizi I., Fauziyah N.F., Hartinawati R., Sholiha Z., An Anti-inflammatory Dental Pulp of Eugenol Extracted from Clove (*Eugenia Caryophyllata*), *Journal of Medicinal and Chemical Sciences*, 2023, **6**:2665 [Crossref], [Publisher]
- [5]. Paula A.B., Laranjo, M., Marto C.M., Paulo S., Abrantes A.M., Fernandes B., Casalta-Lopes J., Marques-Ferreira M., Botelho M.F., Carrilho E., Evaluation of dentinogenesis inducer biomaterials: an in vivo study, *Journal of Applied Oral Science*, 2019, **28** [Crossref], [Google Scholar], [Publisher]
- [6]. Ariesdyanata C., Lunardhi C.G.J., Subiwahjudi A., Differences in Angiogenesis in the Pulp After Application of Propolis Extract and Calcium Hydroxide, *Conservative Dentistry Journal*, 2019, **9**:48 [Crossref], [Google Scholar], [Publisher]
- [7]. Widjiastuti I., Setyabudi Haliza N.N., Rasyid H.N., the Effect of Combination Calcium Hydroxide and Propolis Application To Number of Neutrophil Cells on Wistar Rat Pulp Perforation, *Biochemical & Cellular Archives*, 2020, **20**:4833 [Google Scholar], [Publisher]

- [8]. Widyastuti N.H., Nugrahani N.A., Awwaliannisa M., Tifani A.S. The Effect of Nanochitosane of Red Snapper Fish Scales (*Lutjanus Sp.*) on Pain and Pulp Inflammation. *Journal of Medicinal and Chemical Sciences*, 2023, **6**:2379 [Crossref], [Publisher]
- [9]. Ratih D.N., Enggardipta R.A., Kartikaningtyas A.T. The Effect of Chitosan Nanoparticle as A Final Irrigation Solution on The Smear Layer Removal, Micro-hardness and Surface Roughness of Root Canal Dentin. *The Open Dentistry Journal*, 2020, **14**:19 [Crossref], [Publisher]
- [11]. Matsunaga T., Yanagiguchi K., Yamada S., Ohara N., Ikeda T., Hayashi, Y., Chitosan monomer promotes tissue regeneration on dental pulp wounds, *Journal of Biomedical Materials Research Part A: An Official Journal of The Society for Biomaterials, The Japanese Society for Biomaterials, and The Australian Society for Biomaterials and the Korean Society for Biomaterials*, 2006, **76**:711 [Google Scholar], [Publisher]
- [12]. Zhu N., Chatzistavrou X., Papagerakis P., Ge L., Qin M., Wang Y., Silver-doped bioactive glass/chitosan hydrogel with potential application in dental pulp repair, *ACS Biomaterials Science & Engineering*, 2019, **5**:4624 [Crossref], [Google Scholar], [Publisher]
- [13]. Whittaker A.L., Liu Y., Barker T.H., Methods used and application of the mouse grimace scale in biomedical research 10 years on: a scoping review, *Animals*, 2021, **11**:673 [Crossref], [Google Scholar], [Publisher]
- [14]. Sumidarti A., Moersidi S.N., Reversible pulpitis accompanied with sinus tract on buccal side of the right maxillary first premolar teeth: case report, *Journal of Dentomaxillofacial Science*, 2019, **4**:120 [Crossref], [Publisher]
- [15]. Orhan E., Maden M., Senguüven B., Odontoblast-like cell numbers and reparative dentine thickness after direct pulp capping with platelet-rich plasma and enamel matrix derivative: a histomorphometric evaluation, *International Endodontic Journal*, 2012, **45**:317 [Crossref], [Google Scholar], [Publisher]
- [16]. Hirschman W.R., Wheeler M.A., Bringas J.S., Hoen M.M., Cytotoxicity comparison of three current direct pulp-capping agents with a new bioceramic root repair putty, *Journal of endodontics*, 2012, **38**:385 [Crossref], [Google Scholar], [Publisher]
- [17]. Tran X., Gorin C., Willig C., Baroukh B., Pellat B., Decup F., Opsahl Vital S., Chaussain C., Boukpepsi T., Effect of a calcium-silicate-based restorative cement on pulp repair, *Journal of dental research*, 2012, **91**:1166 [Crossref], [Google Scholar], [Publisher]
- [18]. Marieta A., Musfiroh I. Article Review: Various Pharmacological Activities of Chitosan Compounds. *Pharmacy*, 2019, **17**:105 [Crossref], [Publisher]
- [19]. Khoroushi M., Foroughi M.R., Karbasi S., Hashemibeni B., Khademi A.A., Effect of Polyhydroxybutyrate/Chitosan/Bioglass nanofiber scaffold on proliferation and differentiation of stem cells from human exfoliated deciduous teeth into odontoblast-like cells, *Materials Science and Engineering: C*, 2018, **89**:128 [Crossref], [Google Scholar], [Publisher]
- [20]. Niwa T., Yamakoshi Y., Yamazaki H., Karakida T., Chiba R., Hu J.C.C., Nagano T., Yamamoto R., Simmer J.P., Margolis H.C., The dynamics of TGF- β in dental pulp, odontoblasts and dentin, *Scientific Reports*, 2018, **8**:4450 [Crossref], [Google Scholar], [Publisher]
- [21]. Prananingrum W., Revianti S., Prameswari N., Potential Application of Chitosan Synthesized From *Penaeus Mondon* as A Direct Pulp Capping Material, *Biochemical & Cellular Archives*, 2021, **21**:3295 [Google Scholar], [Publisher]
- [22]. Hartomo B.T., Firdaus F.G., Pemanfaatan biomaterial kitosan dalam bidang bedah mulut, *B-Dent J Kedokt Gigi Univ Baiturrahmah*, 2019, **6**:62 [Crossref], [Google Scholar], [Publisher]
- [23]. Elsoud M.M.A., Elmansy E.A., Abdelhamid S.A., Economic and Non-Seasonal Source for Production of Chitin and Chitosan, *Journal of Chemical Reviews*, 2022, **4**:222 [Crossref], [Google Scholar], [Publisher]
- [24]. Bashandeh Z., Dehno Khalaji A., An efficient removal of methyl green dye by adsorption onto new modified chitosan Schiff base, *Journal of Medicinal and Nanomaterials Chemistry*, 2023, **5**:243 [Crossref], [Publisher]
- [25]. Sarathi R., Devi L.R., Sheeba N., Esakki E.S., Sundar S.M., Photocatalytic degradation of malachite green dye by metal oxide

nanoparticles-mini review, *J. Chem. Rev.*, 2023, 5:15 [[Crossref](#)], [[Google Scholar](#)], [[Publisher](#)]
[26]. Saleh M., Essawy E., Shaalan M., Osman S., Ahmed F., El-Matbouli M., Therapeutic intervention with dietary chitosan nanoparticles alleviates fish pathological and molecular systemic inflammatory responses against infections, *Marine drugs*, 2022, 20:425 [[Crossref](#)], [[Google Scholar](#)], [[Publisher](#)]

HOW TO CITE THIS ARTICLE

Noor Hafida Widyastuti*, Risya Cilmiaty, Adi Prayitno, Brian Wasita, Soetrisno Soetrisno, Comparison between Nanochitosane and Calcium Hydroxide on BMP-2 and TGF- β 1 Levels in Pulp Capping Treatment (In Vivo Study). *J. Med. Chem. Sci.*, 2024, 7(5) 681-687.

DOI: <https://doi.org/10.26655/JMCHMSCI.2024.5.4>

URL: https://www.jmchemsci.com/article_190512.html