

Effects of Ethanol Extract of Propolis on Repair Optic Nerve Damage in a Rat Model for Diabetes Mellitus (Study of MDA, CRP, Caspase-3, and TGF- β Expression and Histopathological Changes on Optic Nerve Damage)

Nur Shani Meida^{1,2*}, Bambang Purwanto¹, Brian Wasita¹, Senyum Indrakila¹, Soetrisno Soetrisno¹, Eti Poncorini¹, Risya Cilmiaty¹

¹Department of Medical Science, Universitas Sebelas Maret, Surakarta, Indonesia; ²Department of Ophthalmology, Medical Education Study Program, Faculty of Medicine and Health Sciences, Universitas Muhammadiyah Yogyakarta, Yogyakarta, Indonesia

Abstract

Edited by: <https://publons.com/researcher/3919871/mirko-spiroski>

Citation: Meida NS, Purwanto B, Wasita B, Indrakila S, Soetrisno S, Poncorini E, Cilmiaty R. Effects of Ethanol Extract of Propolis on Repair Optic Nerve Damage in a Rat Model for Diabetes Mellitus (Study of MDA, CRP, Caspase-3, and TGF- β Expression and Histopathological Changes on Optic Nerve Damage). Open-Access Maced J Med Sci. 2022 Mar 05; 10(A):444-449. <https://doi.org/10.3889/oamjms.2022.8646>

Keywords: Diabetes mellitus; Ethanol extract of propolis; Optic nerve; Oxidative stress

*Correspondence: Nur Shani Meida, Department of Medical Science (doctoral studies), Universitas Sebelas Maret, Surakarta, Indonesia.

E-mail: nurshani_meida@yahoo.com

Received: 06-Feb-2022

Revised: 15-Feb-2022

Accepted: 23-Feb-2022

Copyright: © 2022 Nur Shani Meida, Bambang Purwanto, Brian Wasita, Senyum Indrakila, Soetrisno Soetrisno, Eti Poncorini, Risya Cilmiaty

Funding: This research did not receive any financial support

Competing Interest: The authors have declared that no competing interest exists

Open Access: This is an open-access article distributed under the terms of the Creative Commons Attribution-NonCommercial 4.0 International License (CC BY-NC 4.0)

BACKGROUND: Hyperglycemia in diabetes increases oxidative stress in the body. It causes optic nerve damage and the risk of glaucoma.

AIM: In this study, we evaluated and analyzed the effect of propolis ethanol extract on the repair of optic nerve damage in a rat model for diabetes mellitus (DM).

STUDY DESIGN: Laboratory experimental using the *post-test-only control group design* was used in this study.

METHODS: A total of 28 male Wistar rats were randomly divided into the following four groups, namely, control (K1), DM (K2), DM with propolis treatment (100 mg/kg) (P1), and DM with propolis treatment (200 mg/kg) (P2). Statistical analysis used ANOVA and Kruskal–Wallis with a significance of $p < 0.05$.

RESULTS: The results showed that Gunung Lawu propolis significantly reduced serum glucose levels, malondialdehyde levels, and C-reactive protein levels ($p < 0.01$). Furthermore, propolis extract significantly decreased caspase-3 expression and TGF- β expression ($p < 0.05$) in the optic nerve. Propolis can significantly repair optic nerve damage (optic nerve necrosis, thinning of the retinal nerve fiber layer, and retinal ganglion cell apoptosis) ($p < 0.01$).

CONCLUSION: The final results showed that most of the beneficial effects of propolis were mediated by the reduction of blood glucose levels in diabetic rats.

Introduction

Propolis is used as a traditional herbal medicine in many countries. The composition of propolis varies and depends on geographical conditions such as plant species, climate, and environmental conditions [1]. In this study, the authors used Mount Lawu propolis from Indonesia; the content of caffeic acid phenethyl ester (CAPE) is $30.24 \pm 3.53 \times 10^{-6}$ g and quercetin $4.42 \pm 0.50 \times 10^{-6}$ g [2].

In 2000, there were about 8.4 million people with diabetes mellitus (DM) and it is estimated that by 2030, this will increase to 21.3 million [3]. Indonesia ranks 4th in the population with a high prevalence of DM after India, China, and the America. According to Riskesdas RI (in 2018), the prevalence of DM at the age of more than 15 years is increasing, in 2013, it

increased from 6.9% to 8.5% [4]. DM can cause several complications in the body [5], [6], cause damage to the optic nerve and can be a risk factor for glaucoma, and can cause blindness [7], [8]. The meta-analysis study reported that the relative risk of DM causing glaucoma was 0.65–4.2 [7], [9]. The prevalence of glaucoma in DM patients ranges from 6.8 to 15.6% [10], [11], [12]. In glaucoma with primary open angle glaucoma, it even reaches 20% [13].

The hyperglycemic state of DM increases reactive oxygen species [14], [15]. Malondialdehyde (MDA) levels can be used as a predictor of oxidative stress levels [16], [17], [18]. Besides this, it will activate caspase-3, causing apoptosis and causing optic nerve damage [19]. Glaucoma is characterized by the gradual destruction of retinal ganglion cells (RGCs) and their axons (axon atrophy) also thinning of the retinal nerve fiber layer (RNFL) which will impair axon

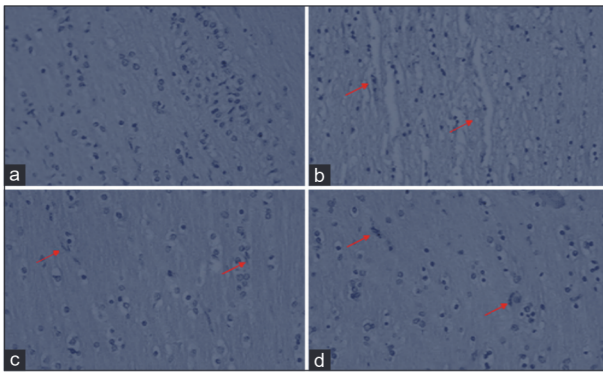


Figure 1: Distribution of the caspase-3 protein in the optic nerve cells expressed by each group (a: A non-diabetic control, b: An untreated diabetes mellitus [DM] group, c: Ethanol extracts of propolis [EEP] 100 mg/kg treated DM group, and d: EEP 200 mg/kg treated DM group) at $\times 400$. Caspase-3 protein expression in cells looks brown (immunohistochemical staining; $\times 400$ – Olympus CX31, Sigma HD Microscope Digital Camera)

transport [20], [21], [22], [23]. Several research reports on antioxidant and anti-inflammatory supplements in helping to optimize glaucoma treatment have been carried out in several countries, but the results have not been satisfactory [24], [25].

Previous findings show that the concentration of propolis compounds is highly dependent on geographic location, environment, and type of vegetation. Until now, there has been no research reporting the effect of Mount Lawu propolis on complications of DM on optic nerve damage.

Methods

Animal

The experimental procedure has been approved by the Ethics Committee issued by the Faculty of Medicine, Public Health and Nursing, Universitas Gadjah Mada, Yogyakarta, with the number KE/FK/0560/EC/2020 on May 11, 2020, and followed the guidelines of the Association for Research in Vision and Ophthalmology Resolution. All procedures were carried out in the laboratory of *Pusat Studi Pangan Gizi* for Animal Care Universitas Gadjah Mada, Yogyakarta, Indonesia.

This research was an experimental laboratory with the *post-test-only control group design*. This study used male Wistar rats aged 8–10 weeks with a bodyweight of 200–250 g. Another alternative is using male Sprague Dawley rats aged 8–10 weeks with a bodyweight of 200–250 g. The use of this type of animal aims to determine the effect *in vivo* which is similar to the human condition because mice have DNA that is more than 90% similar to humans. If propolis is proven to have benefits, it will be used for humans. At

present, Wistar rats or Dawley Sprague are the types most often used in diabetic models. Male Wistar rats are used because they are more stable, are not affected by hormones, and do not interfere with animal reproduction or reproduction. Age 8–10 weeks is the age of adult rats and bodyweight 200–250 is the ideal or normal weight at that age. Euthanasia was performed by administering an ether mask for a few minutes until the animal was unconscious, then, the eye tissue was taken and killed. Euthanasia was carried out at the UGM PAU Lab. PAU UGM laboratory assistants are very experienced in this matter. Animal tissue is not shared with other researchers. Wistar rats were put into cages with room temperatures ranging from 25 to 28°C. Types of food and beverages in the form of standard pellet food and beverages come from the Drinking Water Company (PAM) *ad libitum*. Rats were adapted for 1 week.

Experimental design and induction of DM

A total of 28 rats were randomly divided into four groups (seven rats per group), namely, non-diabetic control (K1), untreated DM group (K2), propolis ethanol extract (EEP) 100 mg/kg diabetes-treated DM group (P1), and 200 mg/kg EEP in the DM group (P2). Rat received carrier propolis (10% ethanol) and EEP at dose levels of 100 and 200 mg/kg body weight administered orally by gastric examination, daily for 14 days, starting after 14 days of being declared post-diabetic. For drug therapy purposes, diabetic and control animals were matched for age.

DM in animals was induced by intraperitoneal injection of a single dose of streptozotocin 45 mg/kg dissolved in 0.1 mol/L citrate buffer. Fifteen minutes before injecting STZ, we injected nicotinamide 110 mg/kg to prevent pancreas [26], [27]. Hyperglycemia was confirmed 72 h after that by measuring ocular venous blood glucose by the Glucose-oxidase-peroxidase aminoantipyrine (GOD-PAP) method. Only animals with average plasma glucose levels > 250 mg/dL were accepted as DM (diabetes status) [28], [29], [30], [31].

Measurement of blood glucose level, MDA level, and CRP level

A total of 24 h after EEP treatment, all rats were anesthetized with ketamine administration. Blood samples were taken from the ophthalmic vein after fasting for 10 h, to measure blood glucose, MDA, and CRP levels. Blood glucose levels were measured by GOD-PAP, MDA levels with thiobarbituric acid reagent, and CRP levels with enzyme-linked immunosorbent assay.

Examination of histopathological changes

The orbits were removed, washed with physiological saline, cleaned of fat, and the optic nerves were examined for caspase-3 expression, TGF- β

expression, and optic nerve damage (optic nerve necrosis, thinning RNFL, and RGC apoptosis). Caspase-3 and TGF- β expression and RGC apoptosis were examined by IHC, optic nerve necrosis, and RNFL by HE.

Statistical analysis

The ratio scale of numerical data (level of GDP, MDA, CRP thickness, and RNFL) was tested using the ANOVA F test and an ordinal scale (caspase-3 expression, TGF- β expression, optic nerve necrosis, and RGC apoptosis) was carried out with a different test using the Kruskal–Wallis test. The test results are considered significant if $p < 0.05$. Data analysis was carried out with Statistical Product and Service Solutions version 24.0 for Windows.

Results

Effect of propolis on blood glucose level (GDP level), MDA level, and CRP level

Figure 1 shows the distribution of the Caspase-3 protein in the optic nerve cells expressed by each group then after H28 or 14 days after propolis administration, the report is shown in Table 1. The ANOVA test on H-28 showed that the levels of GDP, MDA, and CRP has a significant difference in all sample groups with a significance level of 0.001 ($p < 0.01$), and after being continued with the *post hoc* LSD test, the results also showed a significant difference between the group.

Table 1: Effect of EEP on GDP level (mg/dL), MDA level (nmol/dL), and CRP level (ng/dL) at H28 (14 days after propolis administration)

S. No.	Parameter	Unit	N group	Mean \pm SD	p
1.	GDP	mg/dL	K1	75.41 \pm 2.23	0.001*
			K2	272.09 \pm 3.23	
			P1	115.87 \pm 5.11	
			P2	98.27 \pm 4.68	
			K1	1.627 \pm 0.286	
2.	MDA	nmol/dL	K2	9.886 \pm 0.486	0.001*
			P1	4.886 \pm 0.495	
			P2	3.539 \pm 0.310	
			K1	3.0556 \pm 0.089	
			K2	18.030 \pm 0.613	
3.	CRP	ng/dL	P1	6.309 \pm 0.424	0.001*
			P2	4.547 \pm 0.084	

Effect of propolis on caspase-3 expression and TGF- β expression

The data then were analyzed using the Kruskal–Wallis test. It can be seen from Table 2. Kruskal–Wallis test at H28 showed that the results of caspase-3 expression and TGF- β expression levels showed significant differences in all sample groups with a significance level of 0.001 (caspase-3) and 0.002 (TGF- β expression) and after being continued with the *post hoc* test LSD also showed significant differences

Table 2: Effect of EEP on caspase-3 and TGF- β expression in optic nerves

S. No.	Parameter	Group	N	Median (minimum–maximum)	p
1.	Caspase-3 expression	K1	7	1 (1–1)	0.001*
		K2	7	3 (2–3)	
		P1	7	2 (2–3)	
		P2	7	2 (1–3)	
2.	TGF beta expression	K1	7	1 (1–1)	0.002**
		K2	7	3 (2–3)	
		P1	7	2 (1–3)	
		P2	7	2 (1–3)	

K1: Non-diabetic control, K2: An untreated diabetes mellitus group, P1: EEP 100 mg/kg treated diabetes mellitus group, P2: EEP 200 mg/kg treated diabetes mellitus group. Data are median (min-max) of the median. *Significance differences 1%.

between groups. This indicates that propolis doses of 100 mg/kg and 200 mg/kg can significantly reduce caspase-3 expression and TGF- β expression in the diabetic rat (Figures 2 and 3).

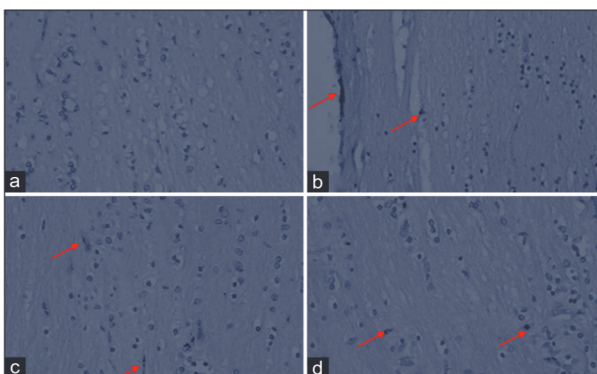


Figure 2: Distribution of optic nerve TGF- β protein expressed by cells in each group (a: A non-diabetic control, b: An untreated diabetes mellitus [DM] group, c: Ethanolic extracts of propolis [EEP] 100 mg/kg treated DM group, and d: EEP 200 mg/kg treated DM group) at $\times 400$. Expression of TGF- β protein in cells looks brown (immunohistochemical staining; $\times 400$ – Olympus CX31, Sigma HD Microscope Digital Camera)

Effect of propolis on optic nerve damage

Optic nerve necrosis

Kruskal–Wallis test at H28 is shown in Table 3, which showed a significant difference in optic nerves

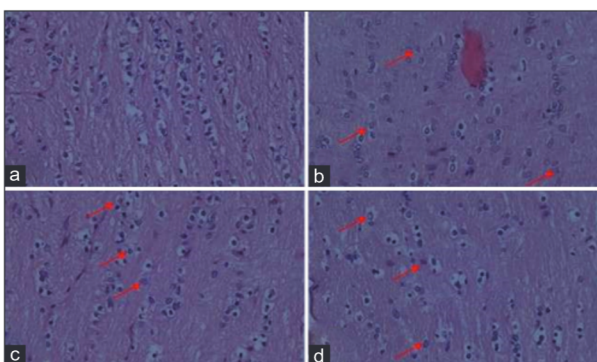


Figure 3: Comparison of retinal nerve fiber layer (RNFL) thickness of each group (a: A non-diabetic control, b: An untreated diabetes mellitus [DM] group, c: Ethanolic extracts of propolis [EEP] 100 mg/kg treated DM group, and d: EEP 200 mg/kg treated DM group) at $\times 400$. RNFL thickness was measured from the inner edge of the retina to the RGC layer (hematoxylin-eosin staining; $\times 400$ – Olympus CX31, Sigma HD Microscope Digital Camera)

Table 3: Differences in mean optic nerve necrosis variables according to the sample group

Group	N	Median (minimum-maximum)	p
K1	7	1 (0–1)	0.001*
K2	7	3 (2–3)	
P1	7	2 (0–2)	
P2	7	2 (0–2)	

K1: Non-diabetic control, K2: An untreated diabetes mellitus group, P1: EEP 100 mg/kg treated diabetes mellitus group, P2: EEP 200 mg/kg treated diabetes mellitus group. Expression level: 0=No necrosis, 1=Necrosis in one place, 2=Necrosis in some places, 3=Necrosis in all places. *Significance differences 1%. Significant at 1% significance degree.

in all sample groups with a significance level of 0.001. After continuing with the LSD *post hoc* test, the results also showed significant differences between groups. This shows that propolis doses of 100 mg/kg and 200 mg/kg can significantly reduce optic nerve necrosis in the diabetic rat as shown in Figure 4.

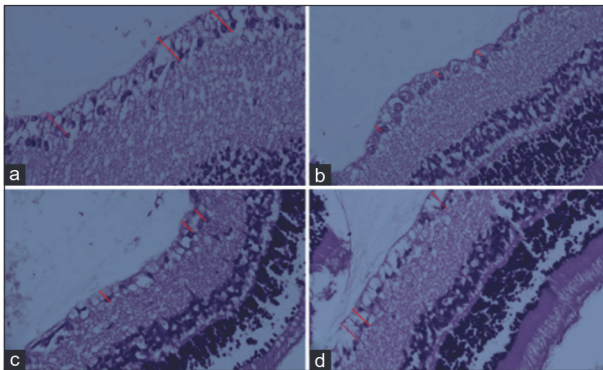


Figure 4: Comparison of caspase-3 expression distribution in RGC (apoptotic RGC) expressed by cells of each group (a: A non-diabetic control, b: An untreated diabetes mellitus [DM] group, c: Ethanol extracts of propolis [EEP] 100 mg/kg treated DM group and d: EEP 200 mg/kg treated DM group) at $\times 400$. Caspase 3 RGC (apoptotic RGC) expression in cells appears brown, (immunohistochemical staining; $\times 400$ – Olympus CX31, Sigma HD Microscope Digital Camera)

Thinning RNFL

The ANOVA test at H28, Table 4, showed a significant difference in RNFL for all sample groups with a significance level of 0.001 ($p < 0.01$), as well as the *post hoc* LSD test. The mean RNFL in K2 decreased significantly ($p < 0.01$) compared to K1 (41.010 ± 7.342 – 125.667 ± 37.283) and after being treated with propolis ethanol extract 100 mg/kg and 200 mg/kg, RNFL in Group P1 80.330 ± 17.378 and P2 125.337 ± 21.381 showed a significant increase ($p < 0.01$) compared to with K2. This shows that propolis doses of 100 mg/kg and 200 mg/kg can significantly increase RNFL in diabetic rats.

Table 4: Differences in average variable thickness retinal nerve fiber layer (pixels) according to sample group

Group	N	Mean \pm SD	p
K1	7	125.667 ± 37.283	0.001*
K2	7	41.010 ± 7.342	
P1	7	80.330 ± 17.378	
P2	7	125.337 ± 21.381	

Table 5: Variable mean differences in caspase-3 expression levels in RGC (apoptotic RGC) according to the sample group.

Group	N	Median (minimum-maximum)	p
K1	7	1 (1–1)	0.001*
K2	7	3 (3–3)	
P1	7	3 (2–3)	
P2	7	2 (2–3)	

K1: Non-diabetic control, K2: An untreated diabetes mellitus group, P1: EEP 100 mg/kg treated diabetes mellitus group, P2: EEP 200 mg/kg treated diabetes mellitus group. Expression level 1=1–30%, 2=31–70%, and 3 = >70%. *Significance differences 1%. RGC: Retinal ganglion cells.

Apoptosis RGC

Kruskal–Wallis test at H28 (Table 5) showed that there were differences in the results of RGC apoptosis in all sample groups with a significance level of 0.001, as well as the *post hoc* test but not significant. This possibility occurs because the propolis dose of 100 mg/kg BW is not sufficient to repair optic nerve damage or the observation time is not long enough. This shows that the propolis dose of 200 mg/kg can significantly reduce RGC apoptosis in diabetic rats.

Discussion

In this study, it was proven that the administration of Mount Lawu propolis ethanol extract in the treatment group significantly reduce blood glucose, MDA and CRP levels, caspase-3, and TGF- β expression improved optic nerve damage (optic nerve necrosis, thinning RNFL, and RGC apoptosis).

The results of this study are by the findings reported from several countries in the world such as Morocco, Iran, and Chihuahua. They reported that the results of the study of propolis can reduce blood glucose levels [18], [32], [33]. Propolis has lowered blood glucose levels. It has been suggested that the glycemic control achieved may be as a result of reduced absorption of carbohydrates in the gut, increased rates of glycolysis, and glucose utilization in the liver, triggering glucose uptake by peripheral tissues such as skeletal muscle cells by activating insulin-sensitive glucose transporters, and inhibition of their release into the circulation from the liver. Propolis extract has a much stronger inhibitory effect on intestinal glycosidase and sucrase than synthetic glycosidase inhibitors such as acarbose. In addition, propolis inhibits the production of glucose from dietary carbohydrates and strongly recommends the use of propolis to control or delay postprandial glucose increases and improves insulin resistance [33].

The current results are in agreement with the findings reported from Iran and Malaysia. They say that propolis can lower MDA levels in diabetic rats. This is related to the antioxidant activity and hypoglycemic effect of propolis. Some evidence suggests that research reports of propolis can significantly lower

CRP levels in diabetic rats. Decreased glucose levels due to propolis administration can reduce oxidative stress, reduce inflammation, and further reduce CRP levels as a biomarker of systemic inflammation [33], [34], [35], [36]. Several research reports the role of propolis as an antioxidant so that oxidative stress decreases and caspase-3 and TGF- β expression decreases [33], [37], [38], [39], [40].

Propolis can repair optic nerve damage in diabetic rats. Green propolis from Brasilia can repair optic nerve damage as seen from the repair of RGC apoptosis and increased retinal thickness in the deep plexiform layer [41]. Several studies reported that CAPE compounds may protect against RGC death. CAPE is a phenolic compound found in propolis, is a strong antioxidant and strong anti-inflammatory, and works by suppressing NF- κ B, through several mechanisms to repair optic nerve damage. The antiapoptotic effect of CAPE on neurons works by reperfusion ischemia or lowering potassium levels by preventing ROS production and inhibiting caspase activity [42]. The novelty of this study is that the administration of Mount Lawu propolis can be a new solution as an alternative therapy in the treatment of optic nerve damage or glaucoma due to DM.

Conclusion

It can be concluded that the ethanolic extract of Gunung Lawu propolis significantly reduced blood glucose, MDA and CRP levels, caspase-3 and TGF- β expression, and repaired optic nerve damage (optic nerve necrosis, thinning RNFL, and RGC apoptosis). However, the limitation of the study needs to be considered. The only used rats were male Wistar, the limited of time (28 days), and propolis administration only 14 days. The glaucoma can be diagnosed by seeing RGC both apoptosis and RNFL depletion. Other observations such as damage to the trabecular meshwork, cup of disk ratio of the optic nerve, and examination of IOP have not been performed. In measuring optic nerve damage, semiquantitative methods used, namely, hematoxylin-eosin and immunohistochemistry staining, but quantitative methods such as RGC counting can be considered.

References

- Sahin H, Aliyazicioglu R, Yildiz O, Kolayli S, Innocenti A, Supuran CT. Honey, pollen, and propolis extracts show potent inhibitory activity against the zinc metalloenzyme carbonic anhydrase. *J Enzyme Inhib Med Chem*. 2011;26(3):440-4. <http://doi.org/10.103109/147563662010503610>

PMid:20687792

- Prasetyo DH, Martini, Syarifah I, Sarsono S. Identification of caffeic acid phenethyl ester in mountain isolate propolis ethanol extract lawu. *J Bahan Alam Indones*. 2012;8(2).
- Ahmed KA, Muniandy S, Ismail IS. Type 2 Diabetes and vascular complications: A pathophysiologic view. *Biomed Res*. 2010;21(2):147-55.
- Perkeni. Konsensus Pengendalian dan Pencegahan Diabetes Mellitus Tipe 2 di Indonesia 2011. Jakarta: Perkeni; 2011.
- Vasudevanand P, Sridhar G. A clinical study of the ocular complications of diabetes mellitus. *IOSR J Dent Med Sci*. 2018;17(3):45-9. Available from: <http://www.iosrjournals.org> [Last accessed on 2021 Sep 14].
- Vieira-Potter VJ, Karamichos D, Lee DJ. Ocular complications of diabetes and therapeutic approaches. *Biomed Res Int*. 2016;2016:3801570. <http://doi.org/10.1155/2016/3801570> PMid:27119078
- Zhao YX, Chen XW. Diabetes and risk of glaucoma: Systematic review and a Meta-analysis of prospective cohort studies. *Int J Ophthalmol*. 2017;10(9):1430-5. <http://doi.org/10.18240/ijo.2017.09.16> PMid:28944204
- Zhou M, Wang W, Huang W, Zhang X. Diabetes mellitus as a risk factor for open-angle glaucoma: A systematic review and meta-analysis. *PLoS One*. 2014;9(8):e102972. <http://doi.org/10.1371/journal.pone.0102972> PMid:25137059
- Zhao D, Cho J, Kim MH, Friedman DS, Guallar E. Diabetes, fasting glucose, and the risk of glaucoma: A meta-analysis. *Ophthalmology*. 2015;122(1):72-8. <http://doi.org/10.1016/j.ophtha.2014.07.051> PMid:25283061
- Beena R, Senthilkumar TG, Raja R. Incidence of glaucoma and diabetic retinopathy in patients with diabetes mellitus in a teaching hospital. *Quest J*. 2017;4:31-5.
- Reddy MM, Malleswari M, Rani KS. Prevalence of primary open angle glaucoma in diabetic patients. *IOSR J Dent Med Sci*. 2017;16(6):147-51.
- Dharmadhikari S, Lohiya K, Chelkar V, Kalyani VK, Dole K, Deshpande M, *et al*. Magnitude and determinants of glaucoma in Type II diabetics: A hospital based cross-sectional study in Maharashtra, India. *Oman J Ophthalmol*. 2015;8(1):19-23. <http://doi.org/10.4103/0974-620X.149858> PMid:25709269
- Jayanta T, Dipali DC, Santana S. Prevalence of Glaucoma Amongst Diabetic Patients Attending a Tertiary Health Care in North Eastern India; 2016.
- Kida T, Hidehiro O, Horie T, Matsuo J, Kobayashi T, Fukumoto M, *et al*. NADPH oxidase-mediated ROS production determines insulin's action on the retinal microvasculature. *Invest Ophthalmol Vis Sci*. 2015;56(11):6754-61.
- Wright E Jr., Scism-Bacon J, Glass L. Oxidative stress in Type 2 diabetes: The role of fasting and postprandial glycaemia. *Int J Clin Pract*. 2006;60(3):308-14. <http://doi.org/10.1111/j.1368-5031.2006.00825.x> PMid:16494646
- Singh Z, Karthigesu IP, Singh P, Kaur R. Use of malondialdehyde as a biomarker for assessing oxidative stress in different disease pathologies: A review. *Iran J Public Health*. 2014;43 Supple 3:7-16. Available from: <https://www.ijph.tums.ac.ir/index.php/ijph/article/view/4858> [Last accessed on 2021 Sep 14].
- Nucci C, Di Pierro D, Varesi C, Ciuffoletti E, Russo R, Gentile R, *et al*. Increased malondialdehyde concentration and reduced total antioxidant capacity in aqueous humor and blood samples from patients with glaucoma. *Mol Vis*. 2013;19:1841-6.

- PMid:23946639
18. Rivera-Yañez N, Rodríguez-Canales M, Nieto-Yañez O, Jiménez-Estrada M, Ibarra-Barajas M, Canales-Martínez MM, *et al.* Hypoglycaemic and antioxidant effects of propolis of chihuahua in a model of experimental diabetes. *Evid Based Complement Alternat Med.* 2018;2018:4360356. <http://doi.org/10.1155/2018/4360356>
PMid:29713363
 19. Gauthier AC, Liu J. Epigenetics and signaling pathways in glaucoma. *Biomed Res Int.* 2017;2017:5712341. <http://doi.org/10.1155/2017/5712341>
PMid:28210622
 20. Vidal-Sanz M, Salinas-Navarro M, Nadal-Nicolás FM, Alarcón-Martínez L, Valiente-Soriano FJ, de Imperial JM, *et al.* Understanding glaucomatous damage: Anatomical and functional data from ocular hypertensive rodent retinas. *Prog Retin Eye Res.* 2012;31(1):1-27. <http://doi.org/10.1016/j.preteyeres.2011.08.001>
PMid:21946033
 21. Galvao J, Davis BM, Cordeiro MF. *In vivo* imaging of retinal ganglion cell apoptosis. *Curr Opin Pharmacol.* 2013;13(1):123-7. <http://doi.org/10.1016/j.coph.2012.08.007>
PMid:22995681
 22. Agudo-Barriuso M, Villegas-Perez M, de Imperial JM, Vidal-Sanz M. Anatomical and functional damage in experimental glaucoma. *Curr Opin Pharmacol.* 2012;13(1):5-11. <http://doi.org/10.1016/j.coph.2012.09.006>
PMid:23041078
 23. Cvenkel B, Kolko M. Current medical therapy and future trends in the management of glaucoma treatment. *J Ophthalmol.* 2020;2020:6138132. <http://doi.org/10.1155/2020/6138132>
PMid:32774906
 24. Yu AL, Moraru O, Erb C, Welge-Lussen U. Effects of micronutrients on serum antioxidant status of glaucoma patients: A randomized, placebo-controlled, double-masked pilot study. *Ophthalmol Res An Int J.* 2014;2(1):1-9.
PMid:25545196
 25. Garcia-Medina JJ, Garcia-Medina M, Garrido-Fernandez P, Galvan-Espinosa J, Garcia-Maturana C, Zanon-Moreno V, *et al.* A two-year follow-up of oral antioxidant supplementation in primary open-angle glaucoma: An open-label, randomized, controlled trial. *Acta Ophthalmol.* 2015;93(6):546-54. <http://doi.org/10.1111/aos.12629>
PMid:25545196
 26. Szkudelski T. Streptozotocin-nicotinamide-induced diabetes in the rat. Characteristics of the experimental model. *Exp Biol Med.* 2012;237:481-90.
 27. Ghasemi A, Khalifi S, Jedi S. Streptozotocin-nicotinamide-induced rat model of Type 2 diabetes (review). *Acta Physiol Hung.* 2014;101(4):408-20. <http://doi.org/10.1556/APhysiol.101.2014.4.2>
PMid:25532953
 28. El-Gohary OA, Said MA. Protective effect of exenatide (glucagon-like peptide-1 receptor agonist) on renal ischemia-reperfusion injury in diabetic rats. *Benha Med J.* 2016;33(1):24. Available from: <http://www.bmfj.eg.net/article.asp?issn=1110-208x;year=2016;volume=33;issue=1;spage=24;epage=30;aulast=el-gohary> [Last accessed on 2021 Sep 13].
 29. Sankaranarayanan C, Pari L. Influence of thymoquinone on glycoprotein changes in experimental hyperglycemic mice. *Int J Nutr Pharmacol Neurol Dis.* 2011;1:51-5.
 30. Rajarajeswari N, Pari L. Antioxidant role of coumarin on streptozotocin-nicotinamide-induced Type 2 diabetic rats. *J Biochem Mol Toxicol.* 2011;25(6):355-61. <http://doi.org/10.1002/jbt.20395>
PMid:21630391
 31. Al-Mahmood SM, Razak TA, Abdullah ST, Fatnoon NA, Mohamed AH, Al-Ani IM. A comprehensive study of chronic diabetes complications in streptozotocin-induced diabetic rat. *Makara J Health Res.* 2016;20(2):48-56.
 32. El Menyiy N, Al-Waili N, El Ghouzi A, El-Guendouz S, Salom K, Lyoussi B. Potential therapeutic effect of Moroccan propolis in hyperglycemia, dyslipidemia, and hepatorenal dysfunction in diabetic rats. *Iran J Basic Med Sci.* 2019;22(11):1331-9. <http://doi.org/10.22038/ijbms.2019.33549.8004>
PMid:32128099
 33. Zakerkish M, Jenabi M, Zaeemzadeh N, Hemmati AA, Neisi N. The effect of Iranian propolis on glucose metabolism, lipid profile, insulin resistance, renal function and inflammatory biomarkers in patients with Type 2 diabetes mellitus: A randomized double-blind clinical trial. *Sci Rep.* 2019;9(1):7289. <http://doi.org/10.1038/s41598-019-43838-8>
PMid:31086222
 34. Hemieda FA, El-Kholy WM, El-Habibi ES, El-Sawah SG. Influence of propolis on oxidative stress, inflammation and apoptosis in streptozotocin-induced diabetic rats. *Int J Adv Res.* 2015;3(7):831-45. Available from: <http://www.journalijar.com> [Last accessed on 2021 Sep 13].
 35. Afsharpour F, Hashemipour S, Haghghighian HK, Koushanc Y. Effects of Iranian propolis on glycemic status, inflammatory factors, and liver enzyme levels in Type 2 diabetic patients: A randomized, double-blind, placebo-controlled, clinical trial. *Clin Trial J Nutr Sci Diet.* 2017;3(2):9-14.
 36. Shang H, Bhagavathula AS, Ali Aldhaleei W, Rahmani J, Karam G, Rinaldi G, *et al.* Effect of propolis supplementation on C-reactive protein levels and other inflammatory factors: A systematic review and meta-analysis of randomized controlled trials. *J King Saudi Univ Sci.* 2020;32(2):1694-701.
 37. Nna VU, Bakar AB, Zakaria Z, Othman ZA, Jalil NA, Mohamed M. Malaysian propolis and metformin synergistically mitigate kidney oxidative stress and inflammation in streptozotocin-induced diabetic rats. *Molecules.* 2021;26(11):3441. <http://doi.org/10.3390/molecules26113441>
PMid:34198937
 38. Taylor AW. Primary open-angle glaucoma: A transforming growth factor- β pathway-mediated disease. *Am J Pathol.* 2012;180(6):2201-4. <http://doi.org/10.1016/j.ajpath.2012.03.011>
PMid:22525463
 39. Murphy-Ullrich JE, Downs JC. The Thrombospondin1-TGF- β pathway and glaucoma. *J Ocul Pharmacol Ther.* 2015;31(7):371-5. <http://doi.org/10.1089/jop.2015.0016>
PMid:26352161
 40. Wang J, Harris A, Prendes MA, Alshawa L, Gross JC, Wentz SM, *et al.* Targeting transforming growth factor- β signaling in primary open-angle glaucoma. *J Glaucoma.* 2017;26(4):390-5. <http://doi.org/10.1097/IJG.0000000000000627>
PMid:28169917
 41. Inokuchi Y, Shimazawa M, Nakajima Y, Suemori S, Mishima S, Hara H. Brazilian Green propolis protects against retinal damage *in vitro* and *in vivo*. *Evid Based Complement Altern Med.* 2006;3(1):71-7. <http://doi.org/10.1093/ecam/nek005>
PMid:16550226
 42. Jia Y, Jiang S, Chen C, Lu G, Xie Y, Sun X, *et al.* Caffeic acid phenethyl ester attenuates nuclear factor- κ B-mediated inflammatory responses in Müller cells and protects against retinal ganglion cell death. *Mol Med Rep.* 2019;19(6):4863-71. <http://doi.org/10.3892/mmr.2019.10151>
PMid:31059064